

A report on Eliza-Jane Scovill's death, in
rebuttal to that of Mohammed Al-Bayati.
Version 2.0

Authored by Nicholas J Bennett MB/BChir, PhD
Clinician and Researcher

Dept of Pediatrics
SUNY Upstate Medical University
750 East Adams Street
Syracuse, NY, 13210
(315) 464 7604
bennetni@upstate.edu

Introduction to Version 1.0

First of all I would add that my motivation to contribute to this story is only through reading the one-sided analysis of Mohamed Al-Bayati, the well-known dissident “doctor” who has in the past promoted his “AIDS cures” while neglecting to acknowledge those who died while trying them, and who calls his few BMJ Rapid Responses “publications” in the BMJ. His analysis of the data is cogent but, predictably, selective in its interpretation.

I wrote to Christine Maggiore as soon as I heard of EJ’s untimely death, expressing my condolences. Regardless of opinion no parent should have to see the death of their child. This is one reason why I find myself now in the field of pediatrics, to help prevent these things from happening. At the time I knew nothing whatsoever about the circumstances surrounding EJ’s death and considered any debate on the matter unnecessary and unhelpful – I said as much publicly on my blog (aidsmyth.blogspot.com) and on the misc.health.aids newsgroup.

Now however I want to set the record straight, or at least the thinking straight, regarding some of the blatant errors put forward by Al-Bayati. While I do not have access to the medical records in their entirety, what Al-Bayati presents alone is sufficient to refute his own analysis.

Please note, Al-Bayati is not a medical doctor, and does not hold an MD degree or a medical license. His only relevant qualification is a toxicology diploma. He is not a pathologist (a type of medical doctor) contrary to the statement made on his own report of EJ’s death, but his PhD is in comparative pathology.

I have a medical degree, have qualified in medicine twice (in the UK and the US), a bachelors in medical science specializing in viral and genetic pathology (I taught virology at Cambridge University for two years) and a PhD in the molecular biology of HIV. In addition I am a resident physician in pediatrics and a sub-investigator on several clinical research studies in pediatric infectious disease. As such I think I am in a better position to interpret the findings of the case as presented, although I too am not a pathologist.

In order to present a succinct rebuttal, I have broken the argument down into several key points.

- 1: The evidence for amoxicillin as a causative/contributory agent
- 2: The evidence for parvovirus B19 as a causative/contributory agent
- 3: The evidence for PCP as a causative/contributory agent
- 4: The evidence for HIV as a causative/contributory agent
- 5: Other factors that may be causative/contributory

Introduction to Version 2.0

I re-wrote parts of this report when I was made aware of the publication of the LA coroners' report on the web. Upon reading this document, which Al-Bayati apparently used as one of his sources (he certainly quotes from it extensively) I was horrified to see that Al-Bayati had not only mis-represented some of the results or presented some findings in a biased light (as I outlined in my original report) but that he had also apparently lied outright about several key points which he used in his own logical arguments.

This second version of my report takes these factors into account and, along with other suggestions that were sent in to me, I hold Al-Bayati accountable for these serious lapses in fact and judgment.

Since the publication of the coroners report readers of my own report can verify the accuracy of my quotes and those of Al-Bayati for themselves. In an age where it is so easy to get misinformation from the Internet, it is refreshing to find that it is just as easy for the reader to judge the truthfulness of the misinformation for themselves.

Looking at the broader picture, I think this is a reflection on the accuracy of the dissident ("HIV does not cause AIDS") misinformation out there, and in addition a reflection on the attitudes of those who are directing the dissident misinformation campaign – those with apparent qualifications who should know better. Such misinformation can lead to people making serious, life-altering decisions about their health – such as refusing to get tested or treated for HIV infection. Such messages are in my experience selectively accepted by those with an existing anti-establishment attitude (such as anti-vaccinationists or those against medical intervention as a whole). I find it sadly ironic that EJ's mother fell into this latter stereotypical category.

Sadly for those who are keen to follow this philosophy, there is a glut of information out there to support their views, and most of the time the evidence to directly contradict it is hidden behind scientific jargon or specialist research papers. In some way perhaps, I am grateful for Al-Bayati's report being made available so that I could so easily demonstrate to the average reader the integrity and accuracy (or rather the lack of both) that permeates the AIDS dissident movement.

I have been involved in arguing against the AIDS dissidents for over 7 years, and in my experience this kind of pseudoscientific babble is entirely typical. I think the public, in particular the lay or semi-specialist AIDS dissidents who lack the focused education, experience or training to know otherwise, need to be made aware of these very serious problems.

The Evidence for Amoxicillin as a Causative/Contributory Agent

Al-Bayati expends a large amount of effort trying to lay blame for much of EJ's decline on the antibiotics prescribed to her in the late stages of her illness. The most convincing aspect of this is perhaps the coincidental timing of the administration of her antibiotics (for a presumed bacterial middle ear infection) and the onset of vomiting, lethargy and ultimately respiratory and cardiac arrest. I note that Al-Bayati actually just calls it cardiac arrest, when the most common situation by far in children is primary respiratory arrest, and this in fact seems to be the case with EJ – the pulseless state apparently described by her father may just be an inability to detect the pulse rather than a true arrest (the reverse is true for adults, who suffer primary cardiac arrests and then respiratory arrest). He then goes on to describe how various aspects of her condition are explained by an allergic response to amoxicillin, one of the beta-lactam group of antibiotics. He states:

“Eliza Jane’s acute symptoms developed following receiving the amoxicillin and the other clinical observations and biomarkers described in her case indicate clearly that she died from acute allergic reaction to amoxicillin.”

This statement makes absolutely no sense.

An acute allergic reaction to ANY drug, in particular one such as amoxicillin, occurs within seconds or minutes of administration. A type I hypersensitivity response is classical, involving IgE, which requires pre-sensitization to the substance. It is well documented that EJ had never before received an antibiotic, and the chances of her being allergic to amoxicillin *a priori* are practically nil. In addition, Al-Bayati goes on to argue that such a response would result in a low blood pressure due to fluid moving out of the blood vessels. While true to some extent, the real reason for a loss of blood pressure during an allergic response to a drug is simply a relaxation of the smooth muscle wall of the blood vessels. This relaxation would be simply and easily treated by administration of epinephrine, and by the administration of fluid boluses. EJ received a total of at least 6 doses of epinephrine and an undisclosed number of fluid boluses, to no effect other than cardiac stimulation and transient improvements in blood pressure. She was in fact in asystole when found by the paramedics and showed a tendency to go into bradycardia and asystole during the attempts to resuscitate here. A true allergic reaction would give her tachycardia as her heart tried to compensate for the relaxed vessels.

A true clinician would know this. In fact, the clinicians treating her clearly did know this, since there is no mention made of any treatment with an antihistamine such as benadryl as would be expected in a classical allergic response to a medication.

He also lays partial blame for her anemia on amoxicillin. He states that there is a “rapid development” of anemia, but gives no explanation for this choice of words as we have no

prior dated results to compare! In fact, it seems more plausible with his mechanism that the anemia is chronic in nature: with a hypoplastic marrow (which he argues is the cause) it would take several weeks to give a meaningful decrease in the red blood count, as the average lifespan of a red blood cell is 120 days.

In addition there is additional evidence that the hypoplastic bone marrow had nothing to do with the decline in red cell counts. For starters there is the fact that her platelet counts and overall white counts were normal, arguing against chronic bone-marrow suppression as the cause for the anemia (regardless of the autopsy findings). Al-Bayati makes mention of a relative lack of neutrophils, but there is also a relatively high number of lymphocytes, indicative of an immune response to a viral infection. Such a shift in cell populations is normal (i.e. in a bacterial infection the shift goes the other way). Most importantly, in aplastic anemia, which Al-Bayati argues is the cause of the low red cell count, there is a RAISED mean cell volume (MCV). EJ's was low at 75.6 (normal range 86-98). And in any case, contrary to Al-Bayati's report, there is no link between amoxicillin and aplastic anemia (marrow suppression).

As such the mechanism proposed by Al-Bayati is entirely bogus, and highlights his lack of clinical training (as well as calling into question his ability to read the literature and his qualifications).

The effects of amoxicillin on the liver are usually only found when used with another drug (clavulanate), and the risk of liver toxicity is around 1-5 in a million. While this of course can't be ruled out, it is unlikely, especially in the short-term (it typically requires several weeks of prolonged therapy). No mention was made of jaundice in EJ, which would be a typical finding in this situation. Without liver function tests being available it is difficult to be sure of the actual status of the liver – all that can be said is that in the absence of fibrosis/cirrhosis any pathology is unlikely to have been chronic in nature. Even if the amoxicillin did adversely affect the liver, in the absence of clinical signs such as jaundice one would be hard pushed to say that there was any clinical significance to it. As regards the lack of apparent hepatomegaly prior to her hospital admission – one obvious caveat is the relative ability of community pediatricians to accurately detect (or even bother to look for) organomegaly, compared to an admitting emergency physician.

My overall opinion of the role of amoxicillin in EJ's death is that it is certainly NOT through the mechanisms proposed by Al-Bayati, but in an extremely rare situation it might have contributed had there been a hemolytic response to the drug (some reports do exist for this). A peripheral blood smear would have very easily confirmed or refuted this as schistocytes (fragmented red cells) might have been seen. In conflict with this conclusion is the small spleen – in hemolysis the spleen is usually enlarged as it chews up the red cells. In addition, the hemolysis typically occurs with high-dose, prolonged therapy (several weeks). In EJ's case, the history of the clinical deterioration was (a) too long to be an allergic response (b) too fast to be a hemolytic response (c) definitely not a marrow suppression response.

Clinical experience with amoxicillin is exceptional – it is a good, safe antibiotic given to thousands of kids and adults daily. The dose administered to EJ was appropriate to her weight and age. My interpretation of the evidence is that the only link between the administration of amoxicillin to EJ and her untimely death is sheer unfortunate coincidence.

The evidence for parvovirus B19 as a causative/contributory agent

Parvovirus B19 is one of a family of small, single-stranded non-enveloped DNA viruses. They have a unique, fascinating replication mechanism that is far too complicated to describe here, but worth mentioning nonetheless. They are generally species-specific and parvovirus B19 is a human strain.

Al-Bayati seems peculiarly fixated upon B19 as a probably causative agent, but ignores several key facts that fail to support the diagnosis and also ignores other perhaps more probable but similar agents – I would argue that he does so in a mistaken attempt to blame certain pre-supposed pathologies on an entity and then try to fit the rest of the picture to that entity (as opposed to trying to find a solution that fits the entire picture).

He states that:

“My investigation indicates that her respiratory infection was probably caused by Human Parvovirus B19 (HPVB19) infection. HPVB19 has been known to cause upper respiratory tract infection, encephalitis, and aplastic anemia in children and adults. Eliza Jane had non-specific microscopic lesions in the brain consisting of microglia and multinucleated giant cells. These lesions could be caused by HPVB19.”

However, as previously stated, the blood results actually don't support a picture of aplastic anemia, as the MCV is low, rather than high. As such, even though a chronic infection with B19 may well lead to aplastic anemia there is little evidence to support this other than post-mortem findings of marrow suppression (which is not well reflected in the other cell lineages, so is likely a recent change). In particular, platelets have a lifespan of only 9-10 days and would be expected to be extremely low in complete marrow suppression of any significant duration. I find it particularly amusing that Al-Bayati has to refer to clinical studies to show that B19 causes aplastic anemia, when this is taught to undergraduate medical students. Statements like this (others are littered throughout his report) do not need literature to support them, as they are simply truisms. All this serves to do is highlight his medical ignorance.

The clinical findings in any case do not resemble a parvovirus B19 infection at all. B19 is known as “slapped cheek disease” or “5th disease”, and is characterized by an appearance of a bright red rash on the face (hence its name) and a lacy rash on the trunk and limbs. No such rash was described by the doctors who examined EJ – presumably if it were Al-Bayati would have mentioned this in support of his hypothesis. In addition, the illness course is typically benign with URI-type symptoms lasting only a few days prior to the appearance of the rash, which disappears in around a week to 10 days.

One caveat to all this is that in a person with *pre-existing anemia* (G6PD deficiency, sickle cell disease and others) the rash is rarely seen and the anemia that B19 can cause is

more severe. Also, and this may be pertinent to later discussion, B19 can be much worse with a longer time course in those who have reduced immunity due to things like HIV infection. However, the anemia is usually present in isolation and easily spotted and treated. In and of itself it should not be fatal.

What is surprising to me is that no other upper respiratory infection was apparently considered by Al-Bayati. He makes no mention of coronavirus, rhinovirus, adenovirus, parainfluenza, enterovirus, HSV, CMV, metapneumovirus, RSV or influenza – the latter five in particular are important as they can result in lower-respiratory tract pneumonias or bronchiolitis. As he is apparently mistaken in assuming that the anemia is aplastic (as shown previously) there is little to no reason to prefer one viral URI over another, and in particular if one is assuming that EJ was previously well then B19 is low down the list of candidates as she presented without the classical rash and had a relatively long infection.

What is frustrating to any attempt to pin blame on a virus entity (as suggest by the blood results, which have the picture of a viral infection) is the complete lack of serology to any virus. The only positive virologic evidence presented is the detection of HIV p24 antigen in the brain as discussed later. Parvovirus B19 is only a reasonable candidate if one assumes that EJ had a pre-existing immune deficiency which resulted in an atypical disease course, without the rash, with a prolonged infection, and with more severe anemia than that normally seen.

Al-Bayati also states that the small spleen and thymus is a result of infection with parvovirus B19. The small spleen in EJ's case is actually most likely normal for her size, and in any case in infection a spleen tends to enlarge rather than shrink (in direct contradiction to Al-Bayati's statement). After the age of around one year she has a remarkably poor growth curve and even at the time of death (where she somehow gains a substantial amount of weight in very short order) she is still only into the 10th-20th centiles. As such, a spleen of 85% normal size for a child of her age is entirely fine, since she herself is small for her age. This is discussed further with in a later section. The causes of actual hyposplenism are few: sickle-cell disease, radiation, coeliac disease, malignancy, ulcerative colitis, alcoholism and drug addiction, tropical sprue, systemic lupus erythematosus, Fanconi's anemia, HIV infection, splenectomy / trauma to spleen, amyloidosis and 'reticulo-endothelial block' (I will confess I had to look those up). The thymus is strikingly small, at around a third of the expected weight. In addition there is fibrosis, suggestive of some chronic cause. Al-Bayati presents a series of references in support of the idea that an acute disease can cause thymic atrophy, and has apparently only read the abstracts to these articles (he quotes them almost verbatim). In one particular case, Zhang states in his abstract:

“Thymuses, spleens, lymph nodes, tonsils and appendices from 621 autopsy cases were reviewed...The main diagnoses of these cases involved more than 130 different diseases...Cases of infection with a course less than 5 days showed mild atrophy of the thymus and those cases with a longer course might show moderate or severe degree of atrophy. ...In 81% of the cases, the degree of thymus atrophy was in accordance with those of the other immune organs.”

And Al-Bayati states:

“Zhang reviewed thymuses, spleens, lymph nodes, tonsils and appendices from 621 autopsy cases. He found that more than 130 different illnesses cause atrophy of the thymus. For example, cases of infection with a course less than 5 days showed mild atrophy of the thymus and those cases with a longer course might show moderate or severe degree of atrophy. In 81% of the cases, the degree of thymus atrophy was in accordance with those of the other immune organs.”

I am unable to corroborate exactly how much atrophy was seen in the cases, since I cannot read Chinese, which is the language which the paper was written in. I leave the reader to judge the quality of work Al-Bayati put into this report.

Regardless of that amusing aside, it is unarguable that an acute infection can result in thymic involution, in particular relatively long-term infections (such as the three-week URI EJ apparently had). In addition thymic involution is also a characteristic of HIV infection (one that is interestingly reversible upon initiating therapy). However, under the circumstances surrounding EJ the ability to lay blame on the thymic involution on HIV as opposed to any other infection is limited. In addition, malnutrition can also apparently have significant effects of thymic size (perhaps explaining why severe malnutrition can also result in an immune-deficiency state). The fibrosis suggests to me a chronic rather than an acute cause of thymic atrophy.

The other area where B19 was implicated by Al-Bayati is in causation of the brain lesions, namely multinucleate giant cells and perivascular inflammation in the white matter and thalamus. In support of this he presents a grand total of 10 case-reports. It is an unusual cause of encephalitis, as highlighted by the report by Barah et al which gave a rate of less than 1 in 20 otherwise undiagnosed meningoencephalitis cases (during a B19 epidemic outbreak). The clinical signs and symptoms of B19 induced brain disease are typically encephalopathic in nature, meaning changes in mental status, personality, seizures and the like. It can rarely progress to multiorgan failure. B19 encephalitis is associated with striking changes on imaging studies, and on biopsy shows necrosis, and generally involves both white and grey matter, neither of which was seen on EJ's postmortem brain histology.

There is however an interesting case report implicating B19 in the case of a 6 year old girl who developed respiratory distress syndrome and multiorgan failure (Ferraz et al, *Pediatric Infectious Disease* 24(11):1009-1010, November 2005).

The main error here though is, again, failure to consider other etiologies of encephalitis because of the original error of incorrectly calling the anemia an aplastic anemia (remembering that the MCV was low, rather than high) and then fixating on B19. There are more than 20 other possible causes of viral encephalitis, some of which are covered by the routine childhood vaccinations which EJ did not receive (measles, mumps, rubella, polio), some are quite unusual and wouldn't be suspected (e.g. dengue), others are

seasonal (e.g. enterovirus in the summer, influenza in the winter). There are also bacterial causes but the blood picture and macroscopic and microscopic examination of the brain don't support this diagnosis.

Overall there is little to no evidence to implicate parvovirus B19 in preference to another virus, although I admit that it is at least a possibility, but ONLY if one assumes that EJ had some form of pre-existing immune dysfunction. Clinically her illness did not resemble normal B19 infection at all. Al-Bayati's attempts to pin various pathological findings on the virus are either bogus or non-specific. I do however agree that in order to rule out B19 as a cofactor one needs to perform specific tests – the best ones would be serology looking for anti-B19 IgM in the CSF or serum. If Al-Bayati really was however trying to formulate a hypothesis for additional pathogens other than PCP or HIV then he really should have cast a far wider net, and at least used evidence that supported his primary alternative diagnosis.

The evidence for Pneumocystis as a causative/contributory agent

The primary evidence for pneumocystis pneumonia (PCP) in contributing to EJ's death is the detection of pneumocystis carinii (now called *Pneumocystis jiroveci*) in the lungs of EJ. PCP is an extraordinarily rare occurrence in the absence of immune compromise either through concurrent infection with another, immune-suppressive organism, or through iatrogenic immune suppression, or through leukemia/lymphoma.

Al-Bayati disregards the whole concept of EJ having a pneumonia by referring to one accepted definition, however in the case of PCP the classical findings of a pneumonia are absent (in fact, in any pneumonia other than a bacterial pneumonia the findings may not be classical). In particular the chest x-ray findings in non-bacterial pneumonia may be quite limited compared to the clinical manifestations. There is quite often a far lower inflammatory exudate for non-bacterial causes. In fact, according to several researchers working on HIV, "PCP is defined as an acute respiratory syndrome that is confirmed by positive morphological staining of *P. carinii* organisms on respiratory samples" in which case EJ clearly meets criteria for PCP, regardless of how Al-Bayati wants to redefine PCP by using a definition of "pneumonia" that suits only his agenda (and that of his paying clients!) (Journal of Clinical Microbiology, March 2000, p. 1307-1308, Vol. 38, No. 3). In addition, the clinical signs of PCP are not the same as those of typical bacterial pneumonias – the fever is lower, there are few crackles or other sounds on auscultation, and shortness of breath is not usually reported except on exertion. Blue lips and other signs of cyanosis are late signs, and in a child are indicative of fulminate collapse.

Findings that are consistent with PCP are foamy alveolar casts and the appearance of fungi under microscopy, or detection of PCP DNA by PCR. Inflammatory cells are normally seen, but far from always (9/13 times in one small series). Pleural effusions are also a complication. On X-ray diffuse, patchy infiltrates are seen. EJ demonstrated alveolar casts (the fluid/inflammatory infiltrate that Al-Bayati says is not present!), PCP-like fungal organisms under microscopy with specific staining, pleural effusions and the initial x-ray also showed diffuse infiltrates. All of these, together, are pointing towards PCP as the likely diagnosis. The later X-ray showed more substantial shadowing, and I agree with Al-Bayati that this most likely is due to an acute process of edema accumulating, most likely as part of acute respiratory distress syndrome (ARDS) although severe PCP can mimic ARDS.

Al-Bayati's complaints about the diagnosis of PCP are invalid:

He states that no findings of inflammation or infiltration were found – to the contrary, foamy alveolar casts (FAC's) were found that are inflammatory infiltrates that are practically diagnostic for PCP (highly sensitive and specific). In several series, FAC's are the only finding that is found in every case. These casts in EJ in addition contained the Pneumocystis organisms, implicating them in causation.

Al-Bayati is fond of quoting the definition of pneumonia involving consolidation of the lung tissue (he quotes it no fewer than five times!) and yet ignores the word “consolidation” in the LA coroners report (it occurs there twice in connection with the examination of the lungs).

One quote states:

“The lower lobes have patchy to spot-like white consolidation. The remaining parenchyma of the other lobes are congested.”

I leave it to the reader to decide whether Al-Bayati is being dishonest or simply shoddy in his analysis of the report. Either conclusion seriously undermines the accuracy of his report on all topics.

PC can indeed be found in other situations, but normally in the absence of any other signs of PCP. The report by Contini et al refers to children with chronic lung disease, a state of health which would make them more susceptible to infection by many agents (i.e. a form of immune compromise). EJ did not have chronic lung disease. Researchers in the literature are at pains to distinguish between PC carriage (which is harmless) and PC pneumonia (which is generally fatal if untreated). It is therefore not only unnecessary for Al-Bayati to try to make a case for PC being a common commensal organism, but disingenuous to suggest that the distinction cannot be made.

He argues that PCP can be caused by infection with PC alongside other immunosuppressive treatments. This is well known, he has no need to argue the case (yet another example of his lack of medical knowledge) and in any case EJ was not treated with any immunosuppressive medications nor did she suffer from leukemia or lymphoma (historically, the only other situations where PCP was seen prior to the AIDS epidemic). Of course, PCP is extremely well known in the AIDS-era due to it being one of the most common causes of death in the developed world from late-stage HIV infection (AIDS).

One other factor which I would expect to be considered is the pulse-oximetry of EJ upon arrival to hospital and during the resuscitation attempts. Al-Bayati makes no mention of this, and yet it is common practice to perform such a simple test (continuous pulse oximetry is non-invasive, easy to set up and gives crucial information on lung ventilation and perfusion). I doubt that it was not done, and Al-Bayati has apparently got access to the medical records of EJ’s admission. I would urge him to disclose these results, as a normal pulse oximetry reading would argue against there being a serious lung condition such as pneumonia. I suspect that such records do exist but are not presented as they conflict with his own opinions of the case. I do normally give people the benefit of the doubt, but the overwhelming evidence from Al-Bayati’s report is that of a pattern of selective disclosure of information to support his case.

In summary, the evidence to support a pathological and clinical diagnosis of pneumocystis pneumonia is overwhelming. In simple PC carriage there is no associated pathology. EJ demonstrated foamy alveolar casts and parenchymal consolidation, respiratory distress and arrest and small pleural effusions, and PC organisms were found on microscopy within the specific pathologic lesions. In normal carriage, detection of PC even with molecular techniques such as immunofluorescence or PCR is unlikely, never mind standard light microscopy.

The evidence for HIV as a causative/contributory agent

The primary evidence for HIV being implicated in the death of EJ is the brain histology. We have no direct evidence for serology for HIV in EJ, and that of her mother is famously inaccurate, at least according to the story told. However, as shown in the prior section, EJ died with a clear case of pneumocystis pneumonia, which is a rare condition in the absence of immune suppression such as HIV infection. There are in addition several other apparently coincidental findings, which are discussed in a later section.

Thymic, splenic and bone marrow atrophy is consistent with HIV infection (although I question whether the spleen is in fact small for EJ, as she is herself underweight as described later). However these are non-specific findings.

Al-Bayati argues that the brain lesions are also non-specific, in particular the microglial nodules characterized by multinucleate giant cells. Al-Bayati quotes a single study of intrauterine infection with parvovirus B19 and extrapolates this to infection in a young child. This is the ONLY study I found linking multinucleate giant cells to parvovirus B19, which is not surprising if it occurs only in fetal infections. In contrast, there are nearly 150 papers linking HIV to the same pathology using very strict search criteria ('HIV multinucleated giant cells brain', versus 'b19 multinucleated giant cells brain'). In fact, multinucleated giant cells are sometimes considered diagnostic for HIV encephalitis, especially when found with microgliosis and myelin pallor (EJ had all three). As such, the vast weight of evidence points to HIV above all other causes, and certainly way above parvovirus B19! In particular, there is an absence of widespread demyelination and the thalamus was involved, which is more in keeping with HIV encephalitis than B19 encephalitis.

Al-Bayati goes on to state that multinucleate giant cells are found in granulomas and are thought to be a result of hyperactivation. However, there were no granulomas found in EJ's brain, and the finding of MGC's in the absence of granulomas is one of the hallmarks of HIV encephalitis, as stated previously. In the case of HIV infection of the CNS, it may be that syncytia formation by HIV is sufficient to create the MGC's (HIV proteins on the cell surface cause fusion much like the virus fuses to the cell when infecting it), in other words they are not a reactive event but a direct cytopathic event.

While there are several experimental and theoretical mechanisms by which MGC's can be created, the fact remains that they are characteristic of HIV encephalitis, even in pre-clinical disease.

Al-Bayati also disputes the accuracy of the testing used to demonstrate HIV-1 antigen in the brain lesions of EJ. Alongside the characteristic histological findings this very clearly points to a diagnosis of HIV encephalitis, and it seems highly unlikely to be otherwise. However, Al-Bayati quotes extensively from the abstract (!) of a single paper (!!)

support his one-sided viewpoint. This paper dates from 1992, and improved sample processing techniques have been in effect since the late 1990's. The papers related in PubMed to this paper all demonstrate good specificity to HIV staining. It is not good scientific practice to cherry-pick evidence to support your view (or that of your paying client). He goes on to say that the immune reaction to amoxicillin (which I have shown did not happen) and the immune reaction to B19 infection (which I have shown did not happen) could cause a false-positive on the antibody tests in the brain. It is clear that Al-Bayati's case is a house of cards that requires multiple dubious, unsupported clauses to be in effect in order to make logical sense.

In addition, the LA coroners report very clearly states that positive and negative controls were used during the p24 antigen testing of the brain sections. Al-Bayati says that such controls were not performed. It is interesting to note that he quotes VERBATIM from the section which mentions the use of controls but DELETED all reference to the use of controls. In fact Al-Bayati specifically states that no control tissue types were used, but the common interpretation of this in the online discussion groups has been that no controls at all were used. This misconception needs to be corrected.

Al-Bayati states:

“Verity also performed select immunohistochemical reactions on the paraffin blocks (1-3, 2-3, and 3-3). These studies included the HIV core protein, p24 and HSV 1 and 2. He stated that strongly positive p24 reactivity was detected in all three sections in the previously described zones of subcortical and deep white matter focal demyelination with microglial-giant cell reaction. No signal was recognized for HSV 1 or 2. Verity concluded that the immunohistochemical study confirms the presence of HIV core protein in the brain sections confirming a diagnosis of HIV encephalitis [1].”

The actual report states:

“Select immunohistochemical reactions were performed on the blocks 1-3, 2-3, and 3-3. These studies included the HIV core protein, p24 and HSV 1 and 2. Appropriate positive [and] negative controls were used on the paraffin sections. A strongly positive p24 reactivity was detected in all three sections in the previously described zones of subcortical and deep white matter focal demyelination with microglial-giant cell reaction. No signal was recognized for HSV 1 or 2.

DIAGNOSIS AND COMMENT

This immunohistochemical study confirms the presence of HIV core protein in the brain sections confirming a diagnosis of HIV encephalitis.”

It is clear to see that as well as being selective in his quotes, and operating from prejudged conclusions, Al-Bayati is apparently unable to type his own reports but prefers to cut and paste from pre-existing text!

I would also expect that some form of HIV serology was done on the blood once HIV was suspected in contributing EJ's death. Al-Bayati does not mention this, and neither does the coroners report (I would not expect such results to be in the admission medical notes, as at that time HIV was not suspected as the patient's clinical history was not fully disclosed). It would however be extremely helpful to know this. If serology were not possible, DNA PCR might be performed on the tissue sections retained for analysis.

In summary, the biochemical evidence for HIV infection in the CNS is robust and sound. Even in the absence of such markers, the pathology found on microscopic examination of EJ's brain is indeed specific for HIV encephalitis, when taken together in the proper context (i.e. EJ is not a fetus, and there were no granulomas present).

Other Factors that may be Causative/Contributory

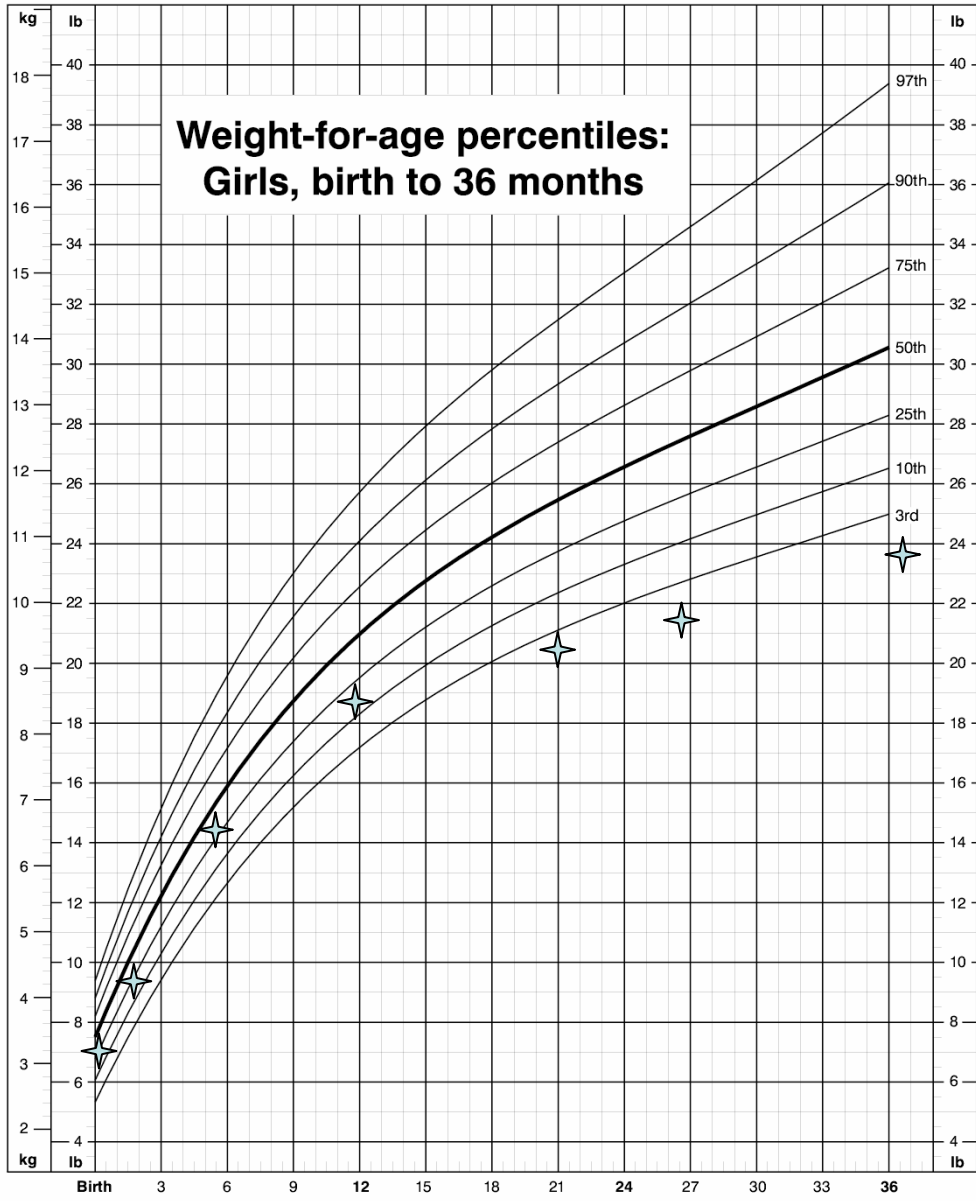
There are several areas of Al-Bayati's report and EJ's story that I think were not given appropriate emphasis, and are significant enough to warrant explanation or investigation. At the very least, they need to be taken into consideration when weighing up all the evidence.

I note that Al-Bayati says that EJ's weight is within the normal range for a child of her age. She is according to him within the 5th centile for her age, but a proper growth chart plot shows that she in fact suffered from a striking failure to thrive from the age of approximately one year. Although she did indeed gain 22 pounds during her life, a child born at 7lbs of weight is expected to weigh 4 pounds more than she did at the age of her death (a difference of around 15% of her actual body mass). In addition, it is clear that this final weight is an aberration from her normal growth curve, as if she had continued along her past track she should have only weighed 26-27lbs at the time of death. The extra 2 lbs (around 900 ml equivalent) is perhaps accounted for by the additional fluid found within and surrounding her organs at the time of death. As such, it appears more likely that the fluid accumulated over time, rather than as a result of simply moving out of the vascular spaces, as if that would have happened her total mass would remain unchanged. Alternatively it may simply be a result of the fluid boluses given to her during resuscitation – without being able to see the actual medical notes I can't say either way. A significant resuscitation of 40ml/kg would account for around half of that additional volume.

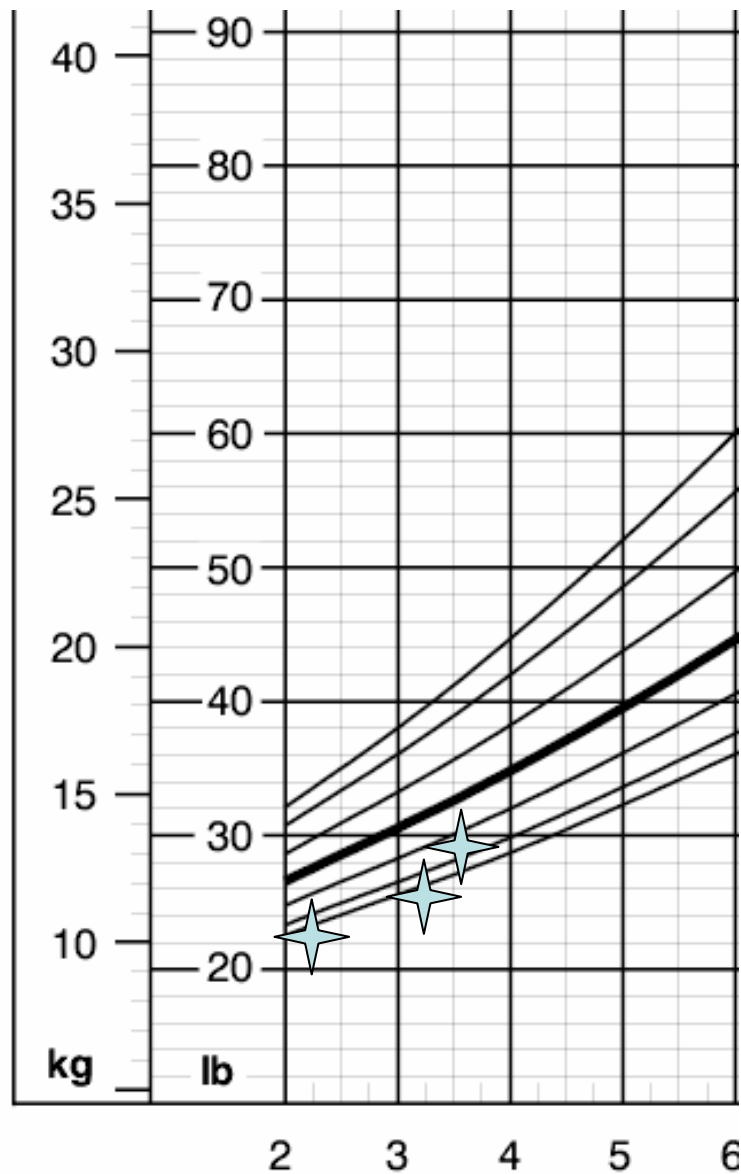
Failure to Thrive is a clinical diagnosis with several possible causes. Most pertinent to this case perhaps are those of malnutrition, emotional distress/neglect and HIV infection. I can see no evidence or reason to suspect that EJ came from anything other than a happy, loving family. There is some evidence for malnutrition in the form of a blood picture that is compatible with iron-deficiency anemia. The other relevant alternative is that of perinatally or post-natally acquired HIV infection.

The following charts better demonstrate the poor growth of EJ – she crosses two percentile lines on the chart. This is diagnostic of Failure to Thrive, as is the fact that she sits below the 3rd centile line. This is typically enough to warn a clinician of some underlying problem, especially worrisome as she is underweight rather than overweight. EJ's weights (taken from Al-Bayati's report) are plotted as blue stars.

CDC Growth Charts: United States



Excerpt from the CDC charts of girls aged 2-20 years, zoomed for clarity. EJ's weights plotted as before.



As such, it would appear to me that EJ had some form of significant clinical problem for the 2 and a half years prior to her death, regardless of her status regarding other childhood illnesses (which by all accounts was unremarkable). Her weight is in lower centiles by my reckoning than what Al-Bayati states, but that may simply be a result of using different growth charts or rounding-up to the nearest line. These charts are the current (2002) versions from the CDC website, accessed Nov 2005. The lowest line is the 3rd centile, which EJ generally remains below. In basic terms, if around 100 kids of the same age were lined up, EJ would have been the smallest.

There is a possibility of a metabolic disorder resulting in failure to thrive, but since she did so well for the first 12 months of her life, I don't consider that a real possibility. Regardless of cause, aged 3.5 years she weighed only as much as a 2.5 year old would normally weigh (and remember, she was born smack in the middle of the spread, at 7 lbs).

Having shown that EJ was in fact significantly smaller than the norm for her age, and that this was in contrast to her normal growth for the first year of life, the observations on the weights of her organs at post mortem is given greater significance than even Al-Bayati puts on them. One would have expected her organs to weigh approximately 85% of the average, and certainly not more than average. At this time I am unable to find tables of growth-specific weights of organs to confirm the statements of Al-Bayati, but since this is presumably concrete evidence I have no reason to suspect that it's wrong in any way. In particular, I am suspicious of the unexpected increase in her total body weight from the last known measurement, and it makes sense that this be accounted for at least partially by a sequestration of fluid in the extravascular spaces and body cavities.

I have since discovered that Al-Bayati was also unable to find the normal weights of the organs at death – these are conveniently provided by the medical examiners report!

As previously mentioned, an allergic reaction to a substance acutely results in a relaxation of blood vessels rather than a leakage of fluid into the extravascular spaces: to accumulate fluid in this manner generally takes a considerable length of time (days or weeks rather than seconds or minutes). Her vascular volume would be maintained by normal homeostatic mechanisms providing sufficient oral fluids were obtained. In such a situation, she would not go into shock. Al-Bayati does not present the results of the blood chemistry other than the bicarbonate and pH values (which are consistent with prolonged respiratory arrest), and these would give at least some clue as to fluid status. However, to get a low hemoglobin level with significant fluid loss is extremely unlikely, since the red cells remain in the vessels and would in fact be concentrated rather than diluted. The picture is certainly one of a gradual accumulation of excess fluid, compensated over time so as to maintain blood pressure, rather than an acute loss of blood pressure due to fluid loss or vessel expansion. Al-Bayati argues that the excess fluid, which he calculates to be around 370ml, has come acutely from her circulating blood volume. In such a situation, she should weigh the same weight, but in contrast she actually showed a striking weight gain from her last measurement out of all proportion to her growth curve of the previous 2 and a half years.

The question then remains: what could cause the accumulation of fluid in these organs, and the pleural effusion and ascites? Pleural effusions are a recognized complication of PCP, especially mild effusions, and EJ's is not striking at only 20ml of fluid (normal fluid is 1ml, and one might expect 50ml to be detectable on a chest-xray even in a young child – in adults it is more like 200ml, which is the lower limit for attempting to drain it).

The fatty liver isn't all that suspicious – steatosis itself can be found in up to 25% of normal people, even in the absence of alcohol ingestion (where it is normally found).

However, accompanied by ascites it suggests some form of liver dysfunction. It can be caused by HIV infection, among others which do not seem to apply to EJ (a list can be found at <http://www.geocities.com/davidscerri/steatosis.htm>). In addition, disseminated pneumocystis infection can also lead to liver enlargement and ascites, although it is not usually present along with pneumocystis pneumonia at the same time. However, AIDS patients do often present with multiple opportunistic infections simultaneously. If EJ was in fact in late stage HIV infection, then other rare causes of liver disease and ascites must be considered, such as mycobacterium avium complex, tuberculosis, bacillary angiomatosis, histoplasmosis, some of which do not appear likely (i.e. no enlarged lymph nodes were found, which would be expected in TB infection) and some of which may explain other findings such as the anemia. However, tests for these were not apparently performed, so any attribution to another pathogen is pure speculation.

One obvious explanation for a system-wide accumulation of fluid, especially in terms of extravasation of fluid from the circulation volume, is nephrotic syndrome. This is a protein-losing renal disease where the oncotic pressure in the blood drops, allowing fluid to escape (this isn't the entire story, but the simple facts are that protein is lost and fluid seeps out...). It can be triggered by a mild infection, or an acute insult to the kidney, or various chronic diseases including HIV (a long list is at <http://www.outlinemed.com/demo/nephrol/9377.htm>).

Nephrotic syndrome however typically causes noticeable swelling as fluid accumulates in the skin. No such swelling was apparently noticed by her parents or medical practitioners. However nephrotic syndrome would explain the following:

The pleural effusion, the ascites, the fatty liver, the cardiac effusion, and overall enlarged organs including the sudden weight gain. Chronic renal disease can also lead to anemia.

In counterpoint to this was the finding that no other abnormality was found on microscopic examination of the kidneys. However, Minimal Change Disease is the most common cause of nephrotic syndrome in children, and can cause nephrotic syndrome in HIV-infected children although other causes are more common in this group of people. Minimal change disease is difficult to detect on normal microscopy of the kidney (hence its name) and especially so in children – it could have been missed by the pathologist examining EJ's kidneys. It is normally treated with steroids, but HIV-related nephrotic syndrome is refractory to this therapy. Serum electrolytes and urinary protein concentrations would assist in making this diagnosis, but are not apparently provided to or considered by Al-Bayati. Nephrotic syndrome might contribute to an immune deficiency due to the loss of antibodies from the circulating plasma. I reiterate that this is a hypothetical diagnosis based on minimal change disease that would be undetected on autopsy.

It should be noted that some people have asked me whether EJ's diet could have contributed to an immune deficiency or anemia (her parents were apparently vegetarians). I do not think this to be the case. While vegetarians are less likely to be obese they aren't really likely to be underweight in my experience. They may be more prone to iron

deficiency anemia (iron is most often found in red meat) but a diet rich in green vegetables should be fine. It would be extraordinarily unlikely to result in an immune deficiency severe enough to result in PCP.

I was also asked how likely it is for a young child infected with HIV to go for 3 years without presenting with another opportunistic infection prior to PCP.

In untreated pediatric AIDS cases, PCP is the most common initial presenting illness (occurring in around 37% of cases overall, and up to 50% in some clinics depending on age). Nearly all undiagnosed HIV+ kids go unnoticed until their initial AIDS-defining illness. In addition, 10% of all cases present for the first time between the ages of 3 and 4 (50% present by the first year of life, and the rate tails off after that). EJ's case is entirely unremarkable. These stats are from the textbook "Pediatric AIDS: 2nd edition".

Overall Summary

I could go on for some time hypothesizing about what happened to EJ, but it is clear that whatever it was, Al-Bayati's report on the case is critically flawed, prejudiced, ill-informed and sadly panders to the expectations of his clients. It should be noted that Al-Bayati is an advisor to Alive and Well, the dissident group which EJ's mother founded. This is a serious conflict of interest.

Al-Bayati's report hinges on selective quotations from abstracts of papers that he does not appear to have read in full-text. His displays recurrent ignorance of clinical and pathological findings and mechanisms. He fails to consider other, more likely diagnoses while disparaging highly likely conclusions from the original report.

It is very, very unlikely that amoxicillin had anything at all to do with EJ's death. The clinical and pathological evidence argues strongly against it. There are other explanations for the effects attributed to amoxicillin by Al-Bayati.

It is also very unlikely that parvovirus B19 had anything to do with EJ's death. Al-Bayati's argument for blaming B19 is an alleged aplastic anemia that is not supported by the blood results, nor the clinical findings. There are other explanations for the effects attribute to B19 by Al-Bayati.

The diagnosis of PCP appears robust, sound, appropriate and in keeping with the medical and scientific literature. It explains her respiratory deterioration, and at the time of respiratory arrest EJ was likely already beyond much help.

The diagnosis of HIV encephalitis also appears robust, sound, appropriate and in keeping with the medical and scientific literature. It explains her failure to thrive, and may also explain some of the findings such as small thymus, enlarged heart and pneumocystis.

In addition, I feel that there is good evidence for a non-infectious contribution to EJ's death in the form of nephrotic syndrome secondary to minimal change disease, possibly triggered by HIV infection or simply bad luck. Nephrotic syndrome is known to predispose children to infection, and may have been the underlying trigger for the transition from PC carriage to PC pneumonia. It also explains the fluid accumulation in the organs and extravascular spaces. However, in the absence of urine analysis and further serum results this is a speculative offering, albeit one that does at least fit the evidence. I do agree with Al-Bayati that the disparity between EJ's low weight and the post-mortem findings of the organ sizes deserves some explanation, and I think that this is ultimately far more likely than some form of sub-acute allergic reaction.

I welcome, as before, comments, corrections, or clarifications.

Nick Bennett MB/BChir, PhD