


12**AUTOPSY REPORT**

No.

2005-03767

SCOVILL, ELIZA

I performed an autopsy on the body of 

at the DEPARTMENT OF CORONER

Los Angeles, California

on MAY 18, 2005 @ 1045 HOURS

(Date)

(Time)

From the anatomic findings and pertinent history I ascribe the death to:

(A) PNEUMOCYSTIS CARINII PNEUMONIA

DUE TO, OR AS A CONSEQUENCE OF

(B) ACQUIRED IMMUNODEFICIENCY SYNDROME

DUE TO, OR AS A CONSEQUENCE OF

(C)

DUE TO, OR AS A CONSEQUENCE OF

(D)

OTHER CONDITIONS CONTRIBUTING BUT NOT RELATED TO THE IMMEDIATE CAUSE OF DEATH.

Anatomical Summary:

1. 3-1/2-year-old girl had a cough and runny nose for three weeks, developed otitis media, T=101.1, received amoxicillin for two days, became irritable and lethargic, found pulseless at home. Rushed to the emergency room, found to have pneumonia, WBC 14,500, Hct 21, MCV 75.6, MCH 22.4, MCHC 29.6 (hypochromic anemia), platelets 214, neutrophils 12%, lymphs 75%, absolute lymphocyte count 10,800, monos 8%, 8 NRBC's. CSF protein 48, glucose 58, no cells. Head CT normal. T=100.6 on arrival.
2. Pale thin body habitus. Crown-heel length 91 cm (5th percentile). Weight 29 pounds (10th percentile).
3. No trauma found at autopsy.
4. Markedly atrophic thymus gland, 8 grams (normal 25-50 grams).
5. Hydrothorax and pericardial effusion. Ascites.
6. The lower lobes of both lungs have patchy to spot-like white consolidation (cultured).
7. Enlarged liver.
8. The vermilion of the upper and lower lips has a tan geographic eschar (cultured and sectioned).
9. Please see separate Microscopic Report, culture reports, Toxicology Report, Neuropathology Report, and Radiology Consult.

12**AUTOPSY REPORT**

No.

2005-03767

SCOVILL, ELIZA

Page 2

CIRCUMSTANCES:

See the Investigator's Report, Form 3.

EXTERNAL EXAMINATION:

The body is identified by toe tags and is that of an unembalmed, refrigerated Caucasian female child who appears about the reported age of 3-1/2 years. The body weighs 29 pounds (10th percentile), measures 91 cm (5th percentile), and is thin. The skin is free of abrasions, lacerations, scars and burns. There are needle puncture sites on the right and left chest, both inguinal areas, sacral area, and back of both hands. There is an area of hyperpigmentation on the right ankle. Rigor mortis is absent. Livor mortis is posterior.

The head is normocephalic and covered by blonde-brown hair. Examination of the eyes reveals irides that appear to be brown in color and sclerae that are unremarkable. There are no petechial hemorrhages of the conjunctivae of the lids or the sclerae. The oronasal passages are unobstructed. Upper and lower teeth are present. The neck is unremarkable. There is no chest deformity. The abdomen is flat. The genitalia are those of a female, and the external genitalia are without trauma or lesions. The extremities show no edema, joint deformity or abnormal mobility.

EVIDENCE OF THERAPEUTIC INTERVENTION:

There is evidence of therapeutic intervention consisting of an endotracheal tube, a nasogastric tube, and a Foley catheter, which are in proper position.

There has not been postmortem intervention for organ procurement.

EVIDENCE OF EXTERNAL TRAUMATIC INJURY:

None.

12**AUTOPSY REPORT**

No.

2005-03767

SCOVILL, ELIZA

Page 3

CLOTHING:

The body is not clothed, and I did not see the clothing.

PRIMARY INCISION:

The standard Y-shaped incision and standard coronal incision are used to enter the body cavities. No foreign material is present in the mouth, upper airway and trachea.

EVIDENCE OF INTERNAL INJURIES:

None.

NECK:

The neck organs are removed en bloc with the tongue. There are white-tan plaque-like lesions on both upper and lower lips. The frenula are unremarkable. No lesions are present, nor is trauma of the gingiva demonstrated. There is slight edema of the aryepiglottic fold. There is no edema of the epiglottis. Both hyoid bone and larynx are intact and without fractures. No hemorrhage is present in the adjacent throat organs, investing fascia, strap muscles, thyroid or visceral fascia. The tongue when sectioned shows no trauma.

CHEST/ABDOMINAL CAVITY:

Both left pleural cavities contain approximately 20 cc of clear serous fluid. No adhesions are present. The lungs are poorly expanded. Soft tissues of the thoracic and abdominal walls are preserved. The organs of the abdominal cavity have a normal arrangement, and none are absent. There are approximately 60 cc of serous fluid in the peritoneal cavity. The peritoneal cavity is without evidence of peritonitis. There are no adhesions.

12**AUTOPSY REPORT**

No.

2005-03767

SCOVILL, ELIZA

Page 4SYSTEMIC AND ORGAN REVIEW

MUSCULOSKELETAL SYSTEM:

No abnormalities of the bony framework or muscles are present.

CARDIOVASCULAR SYSTEM:

The aorta is elastic and of even caliber throughout, with vessels distributed normally from it. The aorta is unremarkable. Within the pericardial sac, there is a minimal amount of serous fluid. The heart weighs 77 grams (expected average weight for age 59 grams). It has a normal configuration. The right ventricle is 0.2 cm thick, and the left ventricle is 0.6 cm thick. The chambers are normally developed and are without mural thrombosis. The valves are thin, leafy and competent. The circumferences of the valve rings are as follows: Tricuspid valve 6.0 cm, pulmonic valve 4.0 cm, mitral valve 5.5 cm, and aortic valve 3.5 cm. There is no endocardial discoloration. There are no lesions of the myocardium. There is no abnormality of the papillary musculature. There are no defects of the septum. The great vessels enter and leave in a normal fashion. The ductus arteriosus is obliterated. The coronary ostia are widely patent, and there is a normal pattern of coronary artery distribution. No focal endocardial, valvular or myocardial lesions are seen. The blood within the heart and large blood vessels is liquid.

RESPIRATORY SYSTEM:

There are scant secretions in the lower bronchial passages. The mucosa is intact and pale. The lungs are subcrepitant, and there is dependent congestion. The left lung weighs 138 grams (expected average weight for age 77 grams), and the right lung weighs 168 grams (expected average weight for age 89 grams). The visceral pleurae are smooth and intact. The parenchymae of the lower lobes of both lungs have patchy to spot-like white consolidations. The remaining parenchymae of the other lobes are congested. The pulmonary vasculature is without thromboembolism.

12**AUTOPSY REPORT**

No.

2005-03767

SCOVILL, ELIZA

Page 5**GASTROINTESTINAL SYSTEM:**

The esophagus is intact throughout. The stomach is not distended and contains a minimal amount of gray-tan mucus. The mucosa is unremarkable. The small intestine and colon are opened along the anti-mesenteric border and show no abnormalities. The appendix is present. The pancreas occupies a normal position and is unremarkable.

HEPATOBIILIARY SYSTEM:

The liver weighs 500 grams (expected average weight for age 413 grams) and is enlarged and tan-brown. The capsule is intact, and the consistency of the parenchyma is soft. The cut surface is smooth with a normal lobular arrangement. The gallbladder is present, and the wall is thin and pliable. It contains less than 5 cc of bile and no calculi. There is no obstruction or dilation of the extrahepatic ducts.

URINARY SYSTEM:

The right kidney weighs 67 grams (expected average weight for age 48 grams), and the left kidney weighs 75 grams (expected average weight for age 49 grams). The kidneys are normally situated, and the capsules strip easily, revealing a smooth surface. The corticomedullary demarcation is preserved. The pyramids are unremarkable. The peripelvic fat is not increased. The ureters are without dilation or obstruction and pursue their normal course. The urinary bladder is unremarkable and contains no urine.

GENITAL SYSTEM:

The uterus is symmetrical and unremarkable. The fallopian tubes, cervix and vagina are unremarkable. The ovaries are normal for age.

12**AUTOPSY REPORT**

No.

2005-03767

SCOVILL, ELIZA

Page 6

HEMATOLYMPHATIC SYSTEM:

The spleen weighs 40 grams (expected average weight for age 47 grams) and is of average size. The capsule is intact. The parenchyma is dark red. There is no increased follicular pattern. There is focal enlargement of the lymph nodes in the mesenteric adipose tissue. The bone is unremarkable. The bone marrow of the vertebra is unremarkable.

ENDOCRINE SYSTEM:

The thyroid is grossly unremarkable. The adrenal glands are unremarkable. The thymus is atrophic and weighs 8 grams (expected average weight for body length 18.7 grams). The pituitary gland is of normal size.

SPECIAL SENSES:

The eyes are not dissected. The middle and inner ears are not dissected.

HEAD AND CENTRAL NERVOUS SYSTEM:

There is no subcutaneous or subgaleal hemorrhage of the scalp. The external periosteum and dura mater are stripped showing no fractures of the calvarium or base of the skull. There are no tears of the dura mater. There is no epidural, subdural or subarachnoid hemorrhage. The brain weighs 1070 grams (expected average weight for age 1141 grams). Please see separate Neuropathology Report for further evaluation.

SPINAL CORD:

The entire spinal cord is not dissected.

NEUROPATHOLOGY:

The brain and dura are placed in 10% formalin solution for further fixation and later neuropathological examination.

12**AUTOPSY REPORT**

No.

2005-03767

SCOVILL, ELIZA

Page 7

TOXICOLOGY:

Heart blood and liver have been submitted to the laboratory, and a SIDS screen has been requested.

SPECIAL PROCEDURES:

Nasal swab, lung viral culture, lung bacterial culture and lower lip ulcer culture have been submitted to the laboratory. A radiology consultation was requested.

HISTOLOGIC SECTIONS:

The heart, right and left lungs, and representative sections from various organs are preserved in four storage jars in 10% formalin. Sections are to be taken in the laboratory after complete fixation; please see separate microscopic report.

WITNESSES:

None.

PHOTOGRAPHY:

One at-scene photo is available. The body is photographed prior to and during the course of the autopsy.

RADIOLOGY:

The entire body was fluoroscoped, and twelve (12) pre-autopsy x-rays were taken of the full body. Please see separate Radiology Consult.

12**AUTOPSY REPORT**

No.

2005-03767

SCOVILL, ELIZA

Page 8

DIAGRAMS USED:

Diagram Forms #16 and 20J were utilized during the performance of the autopsy. The diagrams are not intended to be facsimiles.


OPINION:

Cause of death is Pneumocystis carinii pneumonia due to Acquired Immunodeficiency Syndrome. Manner of death is natural.



CHANIKARN CHANGSRI, M.D.
ASSOCIATE DEPUTY MEDICAL EXAMINER

9/15/05
DATE



JAMES K. RIBE, M.D.
SENIOR DEPUTY MEDICAL EXAMINER

9. 15. 05
DATE

CC:JKR:am/tm:c/f
T-06/02/05

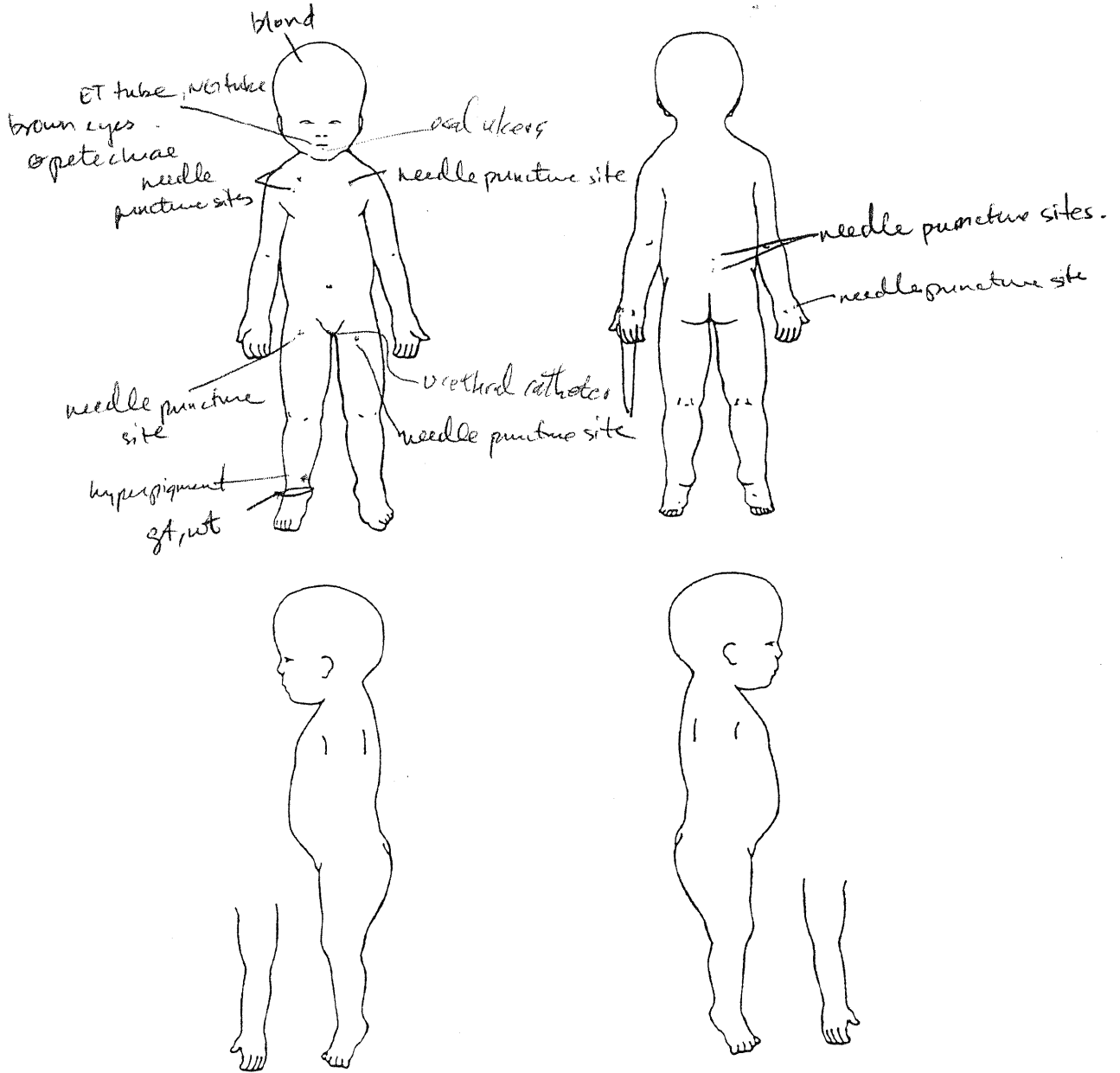
20_J

Pale thin white female child

white-tan plaque like oral lesions on upper and lower lip

2005-03767
SCOVILL, ELIZA

20



Date 5-18-05

[Signature] M.D.
Deputy Medical Examiner.

13NEUROPATHOLOGY

2005-03767

SCOVILL, ELISA JANE

September 14, 2005


MICROSCOPIC DESCRIPTION:

ADDENDUM:

Select immunohistochemical reactions were performed on blocks 1-3, 2-3 and 3-3. These studies included the HIV core protein, P24 and HSV 1 and 2. Appropriate positive negative controls were used on the paraffin sections. A strongly positive P24 reactivity was detected in all three sections in the previously described zones of subcortical and deep white matter focal demyelination with microglial-giant cell reaction. No signal was recognized for HSV 1 or 2.

DIAGNOSIS AND COMMENT:

This immunohistochemical study confirms the presence of HIV core protein in the brain sections confirming a diagnosis of HIV encephalitis.



MAURICE A. VERITY, M.D.
NEUROPATHOLOGY CONSULTANT

DATE 9.14.05

MAV:mtm:c
T: 9/14/05

13NEUROPATHOLOGY

2005-03767

SCOVILL, ELISA JANE

July 6, 2005


MICROSCOPIC DESCRIPTION:

Three H&E stained slides are presented. Two slides representing the parietal cortex and inferior temporal lobe with hippocampal formation reveals similar changes. Overlying leptomeninges and the subarachnoid compartment is unremarkable. The cortical lamination is slightly immature with no suggestion ischemic-hypoxic change. Scattered throughout the white matter with relative sparing of cortex are a number of variable sized microglial nodules characterized by multinucleate giant cells. These zones are associated with moderate pallor and myelination, occasional microphages and have an angiocentric pattern. Necrosis and organisms are not identified. The hippocampal formation is intact with no selective ischemic change throughout CA4-CA1 pyramidal neuronal sectors. Similar encephalitic changes are noted in the thalamus.

FINAL NEUROPATHOLOGIC DIAGNOSIS:

- A. 1. Microglial nodule formation with multinucleate giant cells, predominantly white matter and thalamus consistent with HIV encephalitis.

Comment: These preliminary sections are strongly suggestive of an HIV encephalitis. We will continue with further investigation including more representative samples and special studies.


MAURICE A. VERITY, M.D.
NEUROPATHOLOGY CONSULTANT

7. 20. 05.
DATE

MAV:mtm:c
T: 7/6/05

13NEUROPATHOLOGY

2005-03767

SCOVILL, ELISA JANE

June 22, 2005

AGE: 3 years

DATE OF DEATH: May 16, 2005

REFERRING DME: Chanikarn Changsri, M.D.

CIRCUMSTANCES:

The decedent had a history of good health. The decedent developed upper respiratory infection which resolved and then developed cough. The decedent saw the physician on several occasions two days prior date and placed on antibiotics for ear infection. On the evening of death, the decedent had been agitated and later collapsed. Paramedics transported the decedent, and she died later that morning. She had been diagnosed with pneumonia.

GROSS DESCRIPTION:

A well-formalin-fixed brain is presented for examination. The fresh weight at the time of removal was 1070 grams. Spinal cord is not received. Dura is submitted in two large segments. Both segments are similar in revealing a pale thin unremarkable dura with patent superior sagittal sinus, transverse sinuses and torcular. There is no suggestion of pigmentary discoloration on subdural or epidural surfaces.

Cerebral hemispheric cortical surface is intact and slightly smooth. Leptomeninges are clear without fibrosis or evidence of subarachnoid hemorrhage. There is no exudation. Mild generalized smoothing and slight swelling are noted throughout the cerebrum. There is no cortical dysplasia. Interhemispheric fissure is in the midline.

Inspection of the basal external surface reveals olfactory bulbs and tracts. Optic chiasm is normally situated and appears well-myelinated without atrophy or asymmetry. Major cranial nerves III, V and VII-VIII are easily identified.

13NEUROPATHOLOGY

2005-03767

SCOVILL, ELISA JANE

Page 2

The vasculature of the circle of Willis reveals a normal configuration without anomaly. There is no suggestion of atherosclerosis. Rectus-orbital cortex is symmetric. There is no suggestion of herniation, and ambient cistern is moderately patent. Pons is of normal configuration and appears symmetric and firm. Medulla is similar, and pyramidal tracts are easily visualized. Folial architecture of cerebellum is unremarkable and symmetric. There is no suggestion of tonsillar enlargement or herniation.

Multiple coronal sections are prepared. These sections reveal a normal configuration and size of the lateral ventricular system throughout its extent. Septum pellucidum is in the midline, and third ventricle is slightly closed. Anterior commissure is visualized. Aqueduct measures approximately 1 mm. Cingulate gyri bilaterally are symmetric and do not reveal sulcal atrophy but mild closure. The overlying cortical ribbon throughout is of normal thickness and coloration without softening or discoloration. The head of caudate, putamen, anterior limb of internal capsule, claustrum, and other regions of basal ganglia are easily visualized. Hypothalamus, mammillary bodies, thalami and hippocampal formations are unremarkable bilaterally.

Transverse sections through the midbrain do not reveal pigmentation of the substantia nigra. Pons is of normal configuration, and there is no flattening or asymmetry to the basis pontis. Medulla reveals symmetric pyramids and inferior olivary nuclei. The floor of the fourth ventricle is flattened, and small segments of choroid plexus are evident. Cerebellar hemispheres are similar in shape and size, and folial architecture appears unremarkable, completely surrounding unremarkable deep cerebellar white matter and nuclei.

Representative tissue is taken for microscopy. Tissue is reserved for storage.

13

NEUROPATHOLOGY


2005-03767

SCOVILL, ELISA JANE

Page 3

GROSS IMPRESSIONS:

A. No abnormality detected (gross examination).



MAURICE A. VERITY, M.D.
NEUROPATHOLOGY CONSULTANT

7-6-05
DATE

MAV:am/hg:c
T-06/23/05

13

05-03767

SCOVILL, ELIZA JANE

RADIOLOGY CONSULT

REQUEST:

Decedent is a 3 1/2 year old Caucasian female who died at home. Evaluate for any trauma or other abnormalities.

FILMS:

Whole body radiographic survey - child.

FINDINGS & IMPRESSION:

Negative exam. There is no radiographic evidence of abuse or non-accidental inflicted trauma. There is no radiographic evidence of skeletal dysplasia or musculoskeletal anomaly.

Donald C. Boger mo
DONALD C. BOGER, M.D.
RADIOLOGY CONSULTANT

5-24-05
Date

DCB/fvh:hw
T/5-24-05

5/27/05 ce

14

I performed a microscopic examination on →

at THE DEPARTMENT OF CORONER

Los Angeles, California

2005-03767
SCOVILL, ELIZA

20

Thirteen slides plus special stain of lungs


Slides RUL, RML, RLL, LUL, LLL show the formalin-inflated lungs sectioned lobe by lobe. All lobes show pink foamy casts in the alveoli with no inflammatory response. GMS stains show teacup-shaped microorganisms in the foamy material in the alveoli.

- Slide 1 heart unremarkable
- Slide 2 liver showing micro- and macrovesicular steatosis
spleen showing markedly decreased white pulp
kidney unremarkable
- Slide 3 thymus gland showing atrophy and fibrosis
- Slide 4 pediatric ovary and fallopian tube unremarkable
pancreas unremarkable
- Slide 5 adrenal glands unremarkable
colon unremarkable
small intestine unremarkable
- Slide 6 lower lip showing ulceration with possible viral inclusions
- Slide 7 epiglottis unremarkable
trachea unremarkable


Bone marrow slide: H&E stained section of decalcified vertebral body shows hypocellular marrow with reduction of all three cell lines. Megakaryocytes are hypolobulated.

Diagnosis:

Pneumocystis carinii pneumonia
Herpetic aphthous ulcer
Marked atrophy of the lymphoid tissues



C. Changsri, MD



James K. Ribe, MD

15

AUTOPSY CLASS: A B C Examination Only D

Date 5/18/05 Time 10:45 Dr. Chargin/Ribe
print

FINAL ON 8/31/05 By _____
print

APPROXIMATE INTERVAL BETWEEN ONSET AND DEATH

2005-03767
SCOVILL, ELIZA

20

DEATH WAS CAUSED BY: (Enter only one cause per line for A, B, C, and D)

IMMEDIATE CAUSE

(A) Pneumocystis carinii pneumonia ← unk
DUE TO, OR AS A CONSEQUENCE OF

(B) Acquired immunodeficiency syndrome ← unk
DUE TO, OR AS A CONSEQUENCE OF

(C) _____
DUE TO, OR AS A CONSEQUENCE OF

(D) _____
Other conditions contributing but not related to the immediate cause of death:

NATURAL SUICIDE HOMICIDE
 ACCIDENT COULD NOT BE DETERMINED

If other than natural causes
HOW DID INJURY OCCUR?

WAS OPERATION PERFORMED FOR ANY CONDITION STATED ABOVE: YES NO

TYPE SURGERY _____ DATE _____

ORGAN PROCUREMENT

TECHNICIAN JT

WITNESSES TO AUTOPSY

EVIDENCE RECOVERED AT AUTOPSY
Item Description:

3 1/2 y. o. leuc. girl

PRIOR EXAMINATION REVIEW BY DME

BODY TAG CLOTHING
 X-RAY (No 2) FLUORO
 SPECIAL MED. RECORDS

PROCESSING TAG
 AT SCENE PHOTOS (No 1)

TYPING BLOOD TAKEN BY _____
SOURCE _____

TOXICOLOGY

NO BLOOD
 Embalmed
 >24 hr in hospital
 Decomposed
 Other _____
Reason _____

SPECIMENS

Collected by C
 HEART BLOOD STOMACH CONT.
 FEMORAL BLOOD BRAIN
 _____ BLOOD SPLEEN
 _____ BLOOD KIDNEY
 BILE VITREOUS
 LIVER _____
 URINE _____
bt

STORAGE JARS

Regular (No 4) Oversize (No _____)

Histopath Cut: Autopsy Lab bt

NO TOXICOLOGY REQUESTED

TOXICOLOGICAL ANALYSES ORDERED

SCREEN: C H T S
 ALCOHOL ONLY
 CARBON MONOXIDE
 NEOGEN SCREEN
 OTHER (specify drug and tissue)
#14

REQUESTED MATERIAL ON PENDING CASES

Police Report Med History
 Tox Histo
 Microbiology Investigations
 Radiology Cons. Eye Path. Cons

Consult on _____
 Brain Submitted Neuro Consult DME to Cut 6-21-05 NP per DME
 Criminalistics GSR Sexual Assault Other

[Signature]
[Signature] DME

16

CHL 91 (5th percentile)

HC 46 (10th P)

2005-03767

SCOVILL, ELIZA

20

EXTERNAL EXAM

Sex female
Race Cauc
Age 3
Height 33 in 91cm
Weight 29 lb (10th percentile)
Hair blond - brown
Eyes brown
Sclera nl
Teeth natural
Mouth oral lesions on upper & lower lips
Tongue nl
Nose nl
Chest
Breasts
Abdomen
Scar
Genital
Edema
Skin
Decub

See Form 20

HEART Wt 77 (59g)
Pericard
Hypert 6/0.2/4
Dilat 5.5/0.6/3.5
Muscle
Valves
Coronar

AORTA nl
VESSELS nl

LUNGS Wt
R 16g (89)
L 138 (77) + L chest 20cc
Adhes
Fluid serous fluid
Atelectasis
Oedema (+)
Congest (+)
Consol
Bronchi
Nodes

PHARYNX
TRACHEA
THYROID
THYMUS 8
LARYNX
HYOID
ABDOMINAL WALL FAT

PERITONEUM

Fluid 60cc ascites
Adhes
LIVER Wt 500 (413g)
Caps
Lobul
Fibros
G B 25cc bile
Calc
Bile ducts
SPLEEN Wt 40 (37g)
Color
Consist
Caps
Malpig
PANCREAS
ADRENALS
KIDNEYS Wt
Caps (48) (49)
Cortex R 67/L 75
Vessels
Pelvis
Ureter
BLADDER empty
GENITALIA
Prost
Testes
Uterus
Tubes
Ovar

BRAIN Wt 1070

Dura (1141g)
Fluid
Ventric
Vessels
Ears
Nasal Sin

PITUITARY nl size

SPINAL CORD

TOXICOLOGY SPECIMENS liver, heart blood

SECTIONS FOR HISTOPATHOLOGY

MICROBIOLOGY nasal swabs, lung vira, oral mucus, lung bacterial

OTHER PROCEDURES NP autopsy photography

GROSS IMPRESSIONS See Dictation

Date 5. 18. 05 Time 10:00 Deputy Medical Examiner [Signature]



Department of Coroner, County of Los Angeles
FORENSIC SCIENCE LABORATORIES
 Toxicology Report



Wednesday, June 22, 2005

To: Dr. Ribe
 Deputy Medical Examiner

PendingTox

Subject: Coroner Case Number 2005-03767 SCOVILL, ELIZA

<u>SPECIMEN</u>	<u>SERVICE</u>	<u>DRUG</u>	<u>LEVEL</u>	<u>UNITS</u>	<u>ANALYST</u>
Blood, Heart					
	Acetaminophen	Acetaminophen	ND		L. Mahanay
	Alcohol	Ethanol	Negative		M. Schuchardt
	Barbiturate	Barbiturates	ND		L. Mahanay
	Cocaine	Cocaine and Metabolites	ND		L. Mahanay
	Methamphetamine	Methamphetamine	ND		L. Mahanay
	Opiates	Codeine	ND		L. Mahanay
	Opiates	Morphine	ND		L. Mahanay
	Outside Test	HIV	Done		Quest Diagnostics
	Phencyclidine	Phencyclidine	ND		L. Mahanay
	Salicylate	Salicylate	ND		L. Mahanay
	Volatiles	Acetone/Methanol/Isopropanol	ND		M. Schuchardt

7/29/05 ec / JKR

Legend:

-
- % Saturation
- *
- Done
- g Grams
- g% Gram Percent
- Inc. Inconclusive
- mEq/l Milli equivalents
- mg Milligrams
- mg/dl Milligram per Deciliter
- mg/l Milligram per Liter
- mmol/l Millimoles per Liter
- ND Not Detected
- Negative
- ng/gm Nanograms per Gram
- QNS Quantity Not Sufficient
- TNP Test Not Performed
- Trace
- ug Micrograms
- ug/g Micrograms per Gram
- ug/ml Microgram per Milliliter

**JOSEPH J. MUTO, CHIEF
 FORENSIC LABORATORIES**

1	APPARENT MODE NATURAL	CASE NO 2005-03767
	SPECIAL CIRCUMSTANCES	CRYPT 20

LAST, FIRST MIDDLE SCOVILL, ELIZA JANE	AKA	#
--	-----	---

ADDRESS 5806 TOBIAS AVENUE	CITY VAN NUYS	STATE CA	ZIP 91411
SEX FEMALE	RACE APPEARS CAUCASIAN	DOB 12/3/2001	AGE 3
HGT 33 in.	WGT 29 lbs.	EYES BROWN	HAIR BROWN
TEETH ALL NATURAL TEETH	FACIAL HAIR NONE	ID VIEW Yes	CONDITION FAIR

MARK TYPE	MARK LOCATION	MARK DESCRIPTION
NOK	ADDRESS	CITY VAN NUYS
		STATE CA
		ZIP 91411
		DATE 5/16/2005
		TIME

BODY VIEWED AT HOSPITAL

LA #	MAIN #	CI #	FBI #	MILITARY #	POB
IDENTIFIED BY NAME (PRINT) R. SCOVILL			RELATIONSHIP FATHER	PHONE (818) 780-0753	DATE 5/16/2005

PLACE OF DEATH / PLACE FOUND HOSPITAL	ADDRESS OR LOCATION 15107 VANOWEN STREET	CITY VAN NUYS	ZIP 91405
VALLEY PRESBYTERIAN HOSPITAL			

PLACE OF INJURY	AT WORK	DATE	TIME	LOCATION OR ADDRESS	ZIP
	No				

DOD 5/16/2005	TIME 05:40	FOUND OR PRONOUNCED BY DR. PETER LIU
-------------------------	----------------------	--

OTHER AGENCY INV. OFFICER LAPD JUVENILE - DETECTIVE H. CASTRILLO	PHONE (818) 756-8748	REPORT NO. 0509-16912	NOTIFIED BY	NO
--	--------------------------------	---------------------------------	-------------	----

TRANSPORTED BY LISA VALENZUELA	TO LOS ANGELES FSC	DATE 5/17/2005	TIME 00:40
--	------------------------------	--------------------------	----------------------

FINGERPRINTS?	No	CLOTHING	No	PA RPT	No	MORTUARY
MED. EV.	No	INVEST. PHOTO #	2	SEAL TYPE	NOT SEALED	HOSP RPT
PHYS. EV.	No	EVIDENCE LOG	No	PROPERTY?	No	HOSP CHART
SUICIDE NOTE	No	GSR NO		RCPT. NO.	206141	PF NO.
						856441

SYNOPSIS
 THE DECEDENT HAD A HISTORY OF GOOD HEALTH. SHE HAD DEVELOPED A RUNNY NOSE ON 04-25-2005 THEN IT RESOLVED AND SHE DEVELOPED A COUGH. SHE SAW THE PHYSICIAN ON SEVERAL OCCASIONS. TWO DAYS BEFORE HER DEATH SHE WAS PLACED ON ANTIBIOTICS FOR AN EAR INFECTION. ON THE EVENING OF HER DEATH SHE HAD BEEN AGITATED AND LATER COLLAPSED, PARAMEDICS TRANSPORTED HER TO THE HOSPITAL AND SHE DIED LATER THAT MORNING. SHE HAD BEEN DIAGNOSED WITH PNEUMONIA. NO AUTOPSY NOTIFICATION WAS REQUESTED.

DENISE BERTONE 419432	<i>Denise Bertone</i> INVESTIGATOR	DATE 5/17/2005	REVIEWED BY <i>[Signature]</i>	DATE 5/16/2005	TIME 16:28
		TIME 15:28			

FORM #3 NARRATIVE TO FOLLOW?



County of Los Angeles, Department of Coroner
Investigator's Narrative



Case Number: 2005-03767

Decedent: SCOVILL, ELIZA

Information Sources:

1. Medical records #856441, Valley Presbyterian Hospital, 15107 Vanowen Street, Van Nuys, CA, 91405, 818-902-2950
2. Christine Joy Maggiore, mother, 5806 Tobias Avenue, Van Nuys, CA, 91411, 818-780-0753

Investigation:

On 05-17-2005 at 0618 hours Dr. Liu of Valley Presbyterian Hospital reported this death to T. Dunn of the coroner's office. The death occurred at a hospital and the decedent was transported to the FSC on 05-17-2005 at 0040 hours. Supervisor C. MacWillie assigned this case to me on 05-17-2005 at 0700 hours.

On 05-17-2005 I spoke with Dennis Sporny of the Microbiology Department of Valley Presbyterian Hospital. He reported that the preliminary blood and cerebrospinal fluid cultures showed no growth at one day.

A routine check in JDIC revealed no arrest history for either parent.

On 05-17-2005 police report DR#0509-16912 was requested from Detective Stogsdill of LAPD Van Nuys Homicide Division, but it had not yet been received at the time of the writing of this report.

Location:

Cardiac arrest: residence- 5806 Tobias Avenue, Van Nuys, CA, 91411

Death: hospital- 15107 Vanowen Street, Van Nuys, CA, 91405

Informant/Witness Statements:

Medical records were received with the decedent's incoming paperwork. The records indicate that Los Angeles City Fire Department RA 239 was dispatched on 05-16-2005 at 0003 hours and responded to the decedent's home at 0006 hours. Upon the paramedics arrival the decedent was found pulseless and apneic on the floor. She was cyanotic with cold extremities and asystolic on the cardiac monitor. Reportedly Eliza had an ear infection for one week and was taking Amoxicillin and Tylenol. Prior to her cardiac arrest she had become lethargic and stopped breathing. CPR and ventilations were done via bag-valve-mask en route to the hospital. The decedent presented to the emergency room at 0026 hours and was intubated on arrival. During the intubation no significant secretions were noted in the oropharynx. ACLS medications were administered and her rectal temperature was measured at 100.6-degrees F. She had a return of pulses at 0039 and was resuscitated from a second code approximately 30 minutes later. A chest x-ray revealed pneumonia and a right mainstem intubation; the endotracheal tube placement was corrected. Dopamine was administered and a head CT was performed; it did not indicate the presence of a bleed, fracture or cerebral edema. While in radiology the decedent was again resuscitated from another cardiac arrest. She was admitted to the Pediatric Intensive Care Unit. A lumbar puncture was performed and the cerebrospinal fluid was clear; both blood and CSF cultures were sent. The decedent's white blood cell count was 14.5 and hemoglobin was 6.3 for a specimen drawn on 05-16-2005 at 0240 hours. Oral lesions were present and her abdomen and liver were distended. The decedent did not respond to treatment and again went into cardiac arrest. Dr. Peter Liu pronounced death on 05-16-2005 at 0540 hours. The history and physical indicates that the decedent had been sick for three weeks with cough congestion and some fever and had been diagnosed with an upper respiratory infection and otitis media. She was not administered antibiotics on her initial visit to the physician. During a follow-up visit, two days before her death, she was given Amoxicillin. She had been irritable on the night before her death, and then became lethargic. Reportedly her condition quickly worsened before she



County of Los Angeles, Department of Coroner
Investigator's Narrative



Case Number: 2005-03767

Decedent: SCOVILL, ELIZA

collapsed. Dr. Liu indicated that the decedent's primary care physicians are Dr. Gordon and Dr. Fleiss. She had not been vaccinated for "various reasons."

On 05-17-2005 I spoke with the decedent's mother, Christine Maggiore, by telephone. Ms. Maggiore has a history of good health and received prenatal care during her pregnancy. There is no history of any alcohol or prescription drug use during the pregnancy. Eliza was born at home with the assistance of a midwife. A nuchal cord was present and it was quickly removed and there appeared to be no ill effects. The decedent has a 7-year-old brother, Charles, who is in good health. The decedent attended school had been healthy although somewhat fragile. During the last week of April she had developed a runny nose with yellow mucus that resolved in a few days. On 04-28-2005 she had a cough with mucus and demonstrated rapid, shallow breathing. On 04-30-2005 she was taken to a pediatrician in Los Angeles and saw a physician who was covering for Dr. Paul Fleiss. Eliza was examined and found to have clear lungs, no fever and her pulse oximetry was normal. On 05-04-2005 the mother took her to Dr. Jay Gordon in Santa Monica for a second opinion. He thought she may have had pneumonia and she was then found to have a "low grade ear infection." Dr. Philip Incao of Colorado who was visiting Los Angeles for a lecture also examined the decedent at her home. He listened to her chest and her cough had since resolved. He noted fluid and redness to her right eardrum. On the night of 05-13-2005 the decedent was agitated and on 05-14-2005 Dr. Incao again examined her. He felt her condition was going to linger so he prescribed Amoxicillin. It was the first time the decedent had been administered antibiotics. They were given by her parents as prescribed. On 05-15-2005 Eliza vomited several times throughout the day and her mother noticed she was pale. After dinner she seemed agitated again and had a fever of 101.1-degrees F., but her extremities felt cold to touch. Ms. Maggiore was talking with Dr. Incao over the telephone when Eliza stopped breathing and "crumpled like a paper doll." Prior to her collapse the decedent appeared agitated and uncomfortable, but there was no change in her mental status. There is no history of any trauma and the decedent had never been vaccinated. The parents had researched and spoken with several physicians regarding the risks of immunizations.

Scene Description:

No scene was visited by coroner personnel.

Evidence:

No physical evidence was collected for this report.

Body Examination:

The decedent was seen lying supine on an autopsy table inside the FSC service floor. She is a female child approximately 33-inches in length and weighs approximately 29 pounds. She has brown hair, brown eyes and natural teeth. A nasogastric tube was present in her right naris and an endotracheal tube was secured in her mouth with tape. Lesions were noted on her lips. Several small skin defects were present to her right upper chest and a small bruise was present on each forearm. The decedent had a decal tattoo on her left forearm. Multiple puncture wounds were noted to both femoral areas and saline locks were present to the dorsum of each hand. A foley catheter was intact.

Identification:

The decedent was identified by her father, Robin Scovill, while at the hospital.

Next of Kin Notification:

The decedent's next of kin is her parents, Robin Kelly Scovill and Christine Joy Maggiore. They were present at the hospital upon their daughter's death.

OB



County of Los Angeles, Department of Coroner
Investigator's Narrative



Case Number: 2005-03767

Decedent: SCOVILL, ELIZA

Tissue Donation:

One Legacy was notified by hospital personnel.

Autopsy Notification:

No autopsy notification was requested for this report. If anything of concern is found during the examination please contact Detective H. Castrillo by telephoning 818-756-8748.

Denise Bertone

DENISE BERTONE 419432

Cheryl MacWillie

CHERYL MACWILLIE

05-17-2005

Date of Report

18

TO REPORT A DEATH — PHONE (323) 343-0711 FAX (323) 222-7041
COMPLETE ALL LINES, USE INK. IF UNKNOWN OR NOT APPLICABLE, SO STATE.

CC# 2005-03767

Valley Presbyterian Hospital
NAME OF FACILITY

05. 3767
Scovill, Eliza

ADDRESS 15107 Vanowen St. HOSPITAL PHONE # 902-2950

NAME OF DECEDENT Eliza Scovill

HOW IDENTIFIED By Parents DOB 12-3-01 AGE 37 SEX F RACE C

DATE OF DEATH 5/16/05 TIME 0540

PRONOUNCED BY Peter Liu, MD MEDICAL RECORD OR PATIENT FILE # 856441

ORGAN/TISSUE DONATION INFORMATION

WAS THE NEXT-OF-KIN APPROACHED REGARDING ORGAN/TISSUE DONATION?

NO YES IF YES WHAT WAS THEIR RESPONSE?

DATE ADMITTED 5/16/05 TIME 0244 0155

SELF AMBULANCE (Name or R.A.#)

FROM Here (STATE WHETHER HOME, HOSPITAL OR OTHER) GIVE ADDRESS (IF HOSPITAL ATTACH THEIR HISTORY)

ADMITTED BY: Liu M.D. PRIMARY ATTENDING PHYSICIAN Liu M.D.

OFFICE PHONE # (818) 902-2909 OFFICE PHONE #

INJURIES DATE TIME PLACE CAUSE (TRAFFIC, FALL, ETC.)

DESCRIBE INJURIES:

CLINICAL HISTORY: 3 y/o c 3 wks w/o URI Sx : Dx c om; Placed on Amox x 480. Progressively became sicker & collapse in Full arrest @ home. Paramedics arrived - pt coded in ER x 2. CRT then in PICU - coded again - No return of pulses.

No hx of immunizations

SURGICAL PROCEDURES: STATE TYPE, DATE, TIME AND RESULTS OF ANY OPERATION OR AMPUTATION PERFORMED

WAS A BULLET OR OTHER FOREIGN OBJECTS RECOVERED? SPECIFY No

LABORATORY: REPORT ON PATHOLOGY SPECIMENS TAKEN DATE & TIME

LABORATORY PHONE NUMBER

MICROBIOLOGY CULTURE RESULTS: NO YES (ATTACH REPORT)

TOXICOLOGY SCREEN: NO YES (ATTACH RESULTS)

RADIOLOGICAL STUDIES: NO YES (ATTACH RESULTS)

REMARKS: ESPECIALLY SYMPTOMS PRECEDING AND DURING TERMINAL EPISODE

Non palpable pulses in spite of fluids; Doppler/Dobut. then pt became bradycardic & did not respond to rate med.

IN MY OPINION, THE CAUSE OF DEATH IS: Sepsis.

BY Liu M.D. -OR- NURSE/HOSPITAL ADMINISTRATOR

OFFICE PHONE # (818) 902-2909 OFFICE PHONE #